


**PATIENT**

Dodger Reibel

**SPECIES**

Feline

**BREED**

DSH

**SEX**

Male Neutered

**AGE**

10.11 years

**WEIGHT**

13.12lbs

**INTERPRETED BY**

 Maggie Machen Lamy,  
 DVM, DACVIM  
 (Cardiology)

**IMAGING PERFORMED BY**

Jessica Miller

**HOSPITAL NAME**

 Long Valley Animal  
 Hospital

**REFERRING VET**

Dr. Earl

**INVOICE**

23416

**DATE**

4/22/22

**PRESENTING CLINICAL SIGNS**

History: Low grade (I-II/VI) cardiac murmur. History of pharyngeal lymphoma and just completed a course of chemotherapy.

-Abnormal PE/Chem/CBC/UA Results: WNL.

**ECHOCARDIOGRAM FINDINGS**

2D, m-mode, color flow and doppler imaging is available. The left ventricular wall is borderline normal in dimension. There is mildly hyperechoic endocardium consistent with fibrosis. The papillary muscles are hyperechoic and slightly enlarged. The left atrium is normal in size. The right atrium is normal in size. The right ventricle appears normal. The mitral valve is normal in structure and mobility. No MR. The tricuspid valve appears normal in structure and mobility. Trace/mild TR. Normal velocity. Blood flow through both the LVOT and RVOT are normal in velocity. No effusions. No obvious cardiac tumors.

**CARDIAC CHART**

FELINE CARDIAC PARAMETERS	BODY WEIGHT (kg)	HR (BPM)	IVSd (cm) (Moise, Pipers)	LVIDd (cm) (Moise, Pipers)	LVWd (cm) (Moise, Pipers)	FS (%)	EF (%)
NORMAL PARAMETER	-----	150-240	0.35-0.55	<2 (mean 1.5)	3.5-0.55	35-67	80-100
PATIENT	6.0	230	0.54	1.38	0.53	57	90
FELINE CARDIAC PARAMETERS	LA/AO (Boon)	LA/AO HEART BASE (Swe) (Abbott)	LA 2D short axis Base view (cm) (Abbott)		LVOT VEL (m/s)	RVOT VEL (m/s)	E max (m/s)
NORMAL	<1.5	<1.3	<1.2		<1.6	<1.3	<0.9
PATIENT	1.1	1.1	1.1		0.7	0.8	NM

*\*Note: All measurements based upon multi-modal images and methods. An average value is reported.*  
 Adapted from June Boon, Veterinary Echocardiography, 1998  
 Abbott J & MacLean H JVIM 2006;20: 111-119, Moise et al. Am J Vet Res 47:1476, 1986. Pipers et al. Am J Vet Res 40:882, 1979.

**INTERPRETATION OF THE FINDINGS & FURTHER RECOMMENDATIONS**

Overtly normal geriatric cardiac structure and function. The left ventricular wall thickness is borderline which may reflect early hypertrophic disease or may simply be a normal variant. Follow up is advised to determine significance. No significant valve leaks are noted, and flow through the great vessels is normal in velocity. No definitive cause is identified for the murmur in this study, making it likely physiologic in origin. Given these findings and a normal LA dimension, no medications are indicated.

No cardiac contraindication for general anesthesia. Should fluid or steroid therapy be indicated in the future, any cat should be monitored for intolerance (changes in RR/RE).

Monitor at home for signs of cardiac compromise, including respiratory changes and/or signs of a blood clot event (paralysis, neurologic changes).



**PATIENT**

Dodger Reibel

**SPECIES**

Feline

**BREED**

DSH

**SEX**

Male Neutered

**AGE**

10.11 years

**WEIGHT**

13.12lbs

**INTERPRETED BY**

Maggie Machen Lamy,  
DVM, DACVIM  
(Cardiology)

**IMAGING  
PERFORMED BY**

Jessica Miller

**HOSPITAL NAME**

Long Valley Animal  
Hospital

**REFERRING VET**

Dr. Earl

**INVOICE**

23416

**DATE**

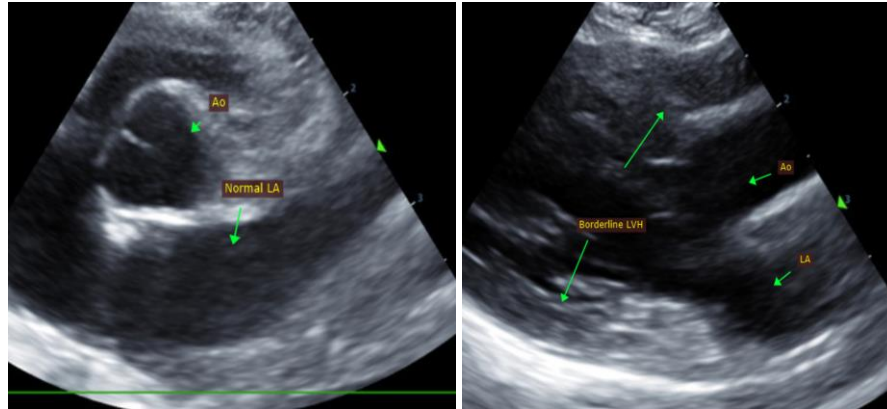
4/22/22

**PLAN**

Baseline BP and T4 are recommended.

Recommend recheck echocardiogram in 6-12 months to screen for progressive issues and development of disease the pre-existing murmur may mask.

**IMAGES**



The information and recommendations provided are based on the images presented by the referring veterinarian. No evaluation can be communicated regarding pathology that was not visible in the image/video clips provided.

Thank you for this referral. This report was generated using transcription software, and minor dictation errors may be present. If the clinical or image interpretation does not parallel your findings or if I can be of any further assistance, please contact me.

**Maggie Machen Lamy, DVM**  
Diplomate of the American College of Veterinary Internal Medicine (Cardiology)  
info@sonopath.com